

Tratamento Cirúrgico da Osteomielite dos Maxilares: Relato de Caso

Surgical treatment of osteomyelitis of the jaws: Case report

Tratamento quirúrgico de la osteomielitis de los maxilares: Reporte de um caso

RESUMO

A Osteomielite dos Maxilares (OM) é uma inflamação óssea, de origem na maioria infecciosa, podendo atingir a porção medular e cortical dos ossos maxilares. Apresenta-se em maior extensão na mandíbula, devido ao pobre suprimento sanguíneo que essa possui, sendo mais prevalente em homens entre a faixa etária de 40 a 60 anos. Sua etiologia está relacionada principalmente às infecções odontogênicas, infecções secundárias e corpos estranhos ocasionais, como os implantes dentários. Tem-se por objetivo apresentar um relato de caso clínico sobre OM na região posterior da mandíbula, bem como sua associação a uma insatisfatória implantação dentária onde houve desenvolvimento de lesão peri-implantar. Paciente do gênero feminino, 53 anos, melanoderma, apresentou dor crônica, abaulamento ósseo sem outros sinais significativos na região de molares inferiores no lado direito, radiograficamente visualizava-se imagem mista sendo sugestiva de sequestro ósseo. Na história pregressa relatou ter realizado explantação na referida região após ser diagnosticada com peri-implantite. Ao final do estudo concluiu-se que a afecção teve como causa a infecção bacteriana proveniente de contaminação durante a inserção de implante dentário. Optou-se por remoção cirúrgica do osso necrótico e inflamado. **Palavras-chaves:** Osteomielite; Crônica; Peri-implantite

Larissa Santana Barros

ORCID: <https://orcid.org/0000-0002-8555-6889>
Universidade de Gurupi - UnirG, Brasil
E-mail: larisantanab@gmail.com

Michelle Rodrigues Andrade

ORCID: <https://orcid.org/0000-0002-2590-8766>
Universidade de Gurupi – UnirG, Brasil
E-mail: michelle.usa@hotmail.com

Jamil Elias

ORCID: <https://orcid.org/0000-0003-0047-4495>
Hospital Estadual de Urgências de Anápolis
Dr. Henrique Santillo, Brasil
E-mail: jamil_dib1@hotmail.com

Márcio Yukio Hassumi

ORCID: <https://orcid.org/0000-0003-4554-9438>
Universidade de Gurupi – UnirG, Brasil
E-mail: marciohassumi@hotmail.com

Vinicius Branco Elias

ORCID: <https://orcid.org/0000-0002-0132-6841>
IAMSPE, Brasil
E-mail: viniciusdib.07@gmail.com

Gabriel Bessa Tibery Tonelli

ORCID: <https://orcid.org/0000-0002-4632-6933>
Universidade de Gurupi – UnirG, Brasil
E-mail: gabrielbessa0412@gmail.com

ENDEREÇO PARA CORRESPONDÊNCIA

Larissa Santana Barros
Rua 17, quadra 16, lote 17, Jardim Arimateia.
Minaçu - Goiás (CEP: 76450-000)
Telefone: 62 99275-7817
E-mail: larisantanab@gmail.com

ABSTRACT

Osteomyelitis of the Jaws (OM) is a bone inflammation, of mostly infectious origin, which can affect the medullary and cortical portion of the maxillary bones. It presents itself to a greater extent in the mandible, due to the poor blood supply that it has, being more prevalent in men between the age group of 40 to 60 years. Its etiology is mainly related to odontogenic infections, secondary infections and occasional foreign bodies, such as dental implants. The objective is to present a clinical case report on OM in the posterior region of the mandible, as well as its association with an unsatisfactory dental implantation, where there was development of a peri-implant lesion. Female patient, 53 years old, melanoderma, presented chronic pain, bone bulging without other significant signs in the region of lower molars on the right side, radiographically a mixed image was visualized, suggesting bone sequestration. In her previous history, she reported having performed explantation in that region after being diagnosed with peri-implantitis. At the end of the study, it was concluded that the disease was caused by bacterial infection from contamination during dental implant insertion. We opted for surgical removal of the necrotic and inflamed bone. Key-words: Osteomyelitis; Chronic; Peri-implantitis

RESUMEN

La osteomielitis de los maxilares (OM) es una inflamación de los huesos, en su mayoría de origen infeccioso, que puede afectar la porción medular y cortical de los huesos maxilares. Se presenta en mayor medida en la mandíbula, debido a la escasa irrigación sanguínea que tiene, siendo más prevalente en hombres entre el grupo de edad de 40 a 60 años. Su etiología se relaciona principalmente con infecciones odontogénicas, infecciones secundarias y cuerpos extraños ocasionales, como los implantes dentales. El objetivo es presentar un reporte de caso de OM en la región posterior de la mandíbula, así como su asociación con una implantación dentaria insatisfactoria a partir de la cual desarrollamos una lesión periimplantaria. Paciente femenina, 53 años, melanodermia, presenta dolor crónico, tumefacción ósea con otros signos significativos en región molar inferior del lado derecho, radiográficamente se visualiza imagen mixta sugestiva de pérdida ósea. En su historia previa menciona haber realizado una explantación en esa región tras ser diagnosticada de periimplantitis. Al final del estudio, se concluyó que la enfermedad fue causada por una infección bacteriana provocada por la contaminación durante la inserción del implante dental. Se optó por la extirpación quirúrgica de la piel necrótica e inflamada. **Palabras clave:** Osteomielitis; Crónica; Periimplantitis.

INTRODUCTION

Osteomyelitis of the jaws (OM) is conceptualized as an inflammation, and it is most often of infectious origin, characterized by invading the bone and its medullary spaces, and its medullary spaces, and may extend from the cortical bone to the periosteum.¹ Thus, the infection causes vascular ischemia and stasis, factors that compromise the diffusion of nutrients and oxygen, the recruitment of defense cells and promote anaerobic bacterial growth, leading to osteonecrosis.²

Given the long existence of OM as a clinical entity, several classifications emerged during the course of the disease evolution process. In turn, the literature objectively proposes a classification system into two main clinical categories, which are described as acute or chronic.³ The first related works in the literature clarified that the differentiation occurred through the clinical course of the condition, with an interval of one month being established. In the past, there was no way to determine a period of time capable of showing when an acute condition, as the infection can persist intermittently for years with frequent therapeutic failures.⁴

Om occurs more frequently in the mandible, since it is a spongy bone, with thin cortical plates and, as it is a medullary tissue, it has a poor vascular supply.^{2, 5, 6, 7}

Generally, the appearance of this oral condition is associated with odontogenic infection, which arises as a result of dental plaques, caries, periodontal disease, periapical abscesses or infection of adjacent soft tissues, contaminated facial fractures or foreign bodies such as implants, wire, plates and screws.^{6, 7}

In view of this, it is necessary to disseminate the theme in question to students and Dental Surgeons, in order to facilitate possible new diagnoses and contribute to the oral health of society. Therefore, the objective is to report a clinical case of OM in the posterior region of the mandible, as well as its probable association with an unsatisfactory adaptation of a dental implant in that location, which was removed due to a periimplantitis condition

CASE REPORT

The present case report is a cross-sectional and descriptive study through the aspects observed in the performance of the biopsy and document analysis, which was carried out through investigation of medical records. The work in question had been documented on the premises of the Clinical School of the Faculty of Dentistry – University of Gurupi (UNIRG), Campus of Gurupi (TOCANTINS). In turn, had its approval by the Research Ethics Committee under opinion 5.344.298, approved on April 11, 2022.

Patient N.C.R, female, 53 years old, melanoderma, in 2019 to a private dentistry clinic reporting painful symptoms in the molar region on the right side of the mandible. Upon clinical examination, a dental implant was found in the region of element 46, which had been rehabilitated with a screw-retained crown and a new healer was removed and installed. Clinically, the gingiva presented with edema on the right side of the mandible and with purulent secretion. The patient underwent sub gingival scaling sessions with temporary improvement of symptoms. After a few months, the patient returned with the same signs and symptoms mentioned above, and radiographically there was significant bone loss with diagnosis of peri-implantitis. The treatment plan proposed at the time of consultation was based on explantation and was performed with a trephine drill. During the surgical procedure, the presence of a foreign material around the implant was noted, suggestive of gauze remnant. The surgical socket was carefully curetted and irrigated with a 0,9% saline solution. In periodic

follow-up, a Computed Tomography (CT) exam was performed, which revealed a lesion with the following characteristics: mixed image located bilaterally in the posterior region of the mandible; there is a greater change in the trabecular bone pattern in the posterior region of the right side with an image suggestive of bone sequestration. (Fig. 1a and 1b).

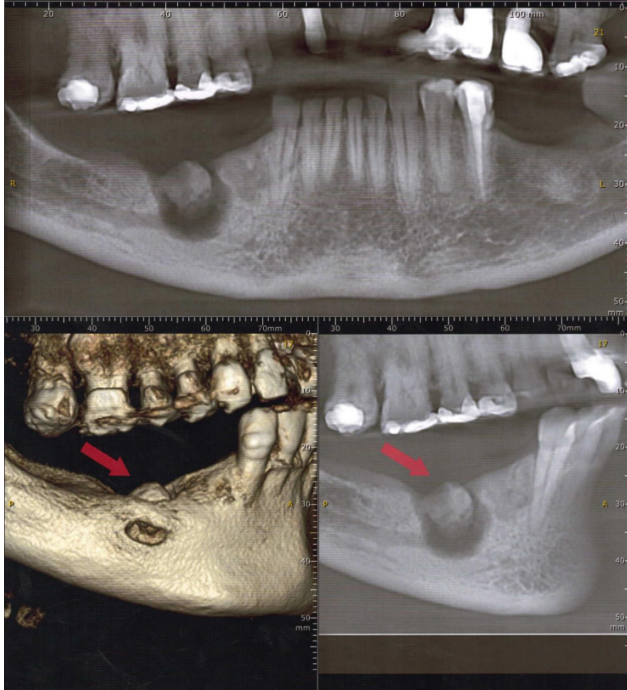


Figura 1 - A – Mixed image located bilaterally in the posterior region of the mandible. B – Image suggestive of bone sequestration.

The patient was referred to the Oral and Maxillofacial Pathology Outpatient Clinic of the Faculty of Dentistry of Gurupi (UNIRG) for a careful evaluation; however, she only attended the School Clinic in 2021. On clinical examination, no extraoral changes were identified, however, in the oral cavity there was the presence of bulging of the cortical bone without other significant signs (Fig. 2a and 2b). The patient reported chronic pain and said she had been on systemic antibiotics for several days.

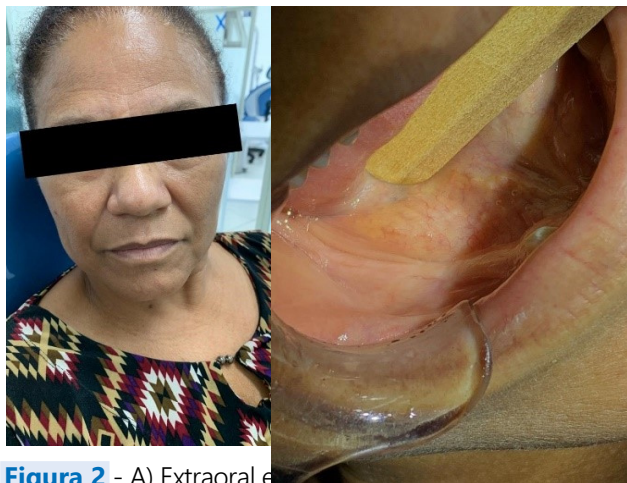

Figura 2 - A) Extraoral e

Adding the information obtained in the anamnesis to the clinical history and images provided by the CT, we opted for an excisional biopsy to even remove healthy bone tissue (Fig. 3a e 3b). The specimen was fixed in 10% formalin solution and sent for histopathological examination (Fig. 3c), the report being compatible with the MO in which the histological sections are represented by necrotic bone tissue, associated with small fragments of densely collagenized tissue (Fig. 3d).

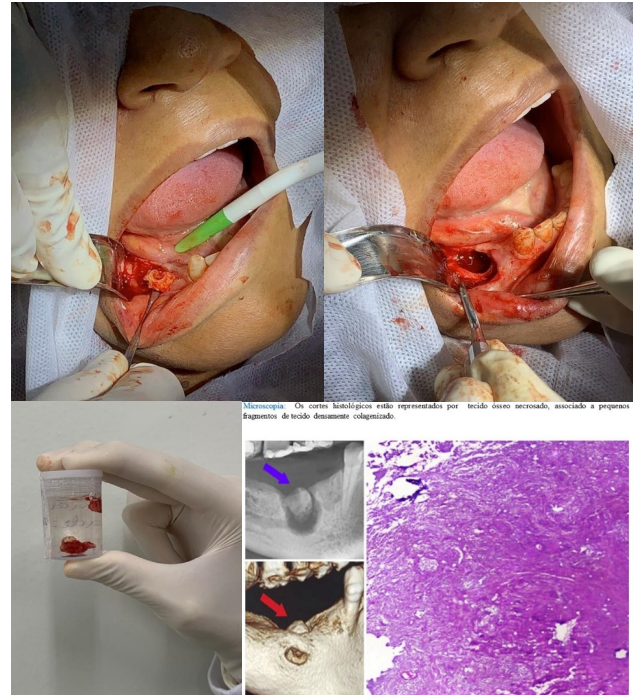

Figura 3 - A – Removal of necrotic bone tissue; B – Cavity tissue removal and curettage; C – Specimen into the container with 10% formalin; D – Histopathological diagnosis.

After the initial procedures, the patient is under evaluation and radiographic control (periapical radiography) for evaluation at 30 days (Fig. 4a) and six months (Fig. 4b), in which subsequent bone neoformations are evidenced and, on local clinical examination, there are no phlogiston signs.

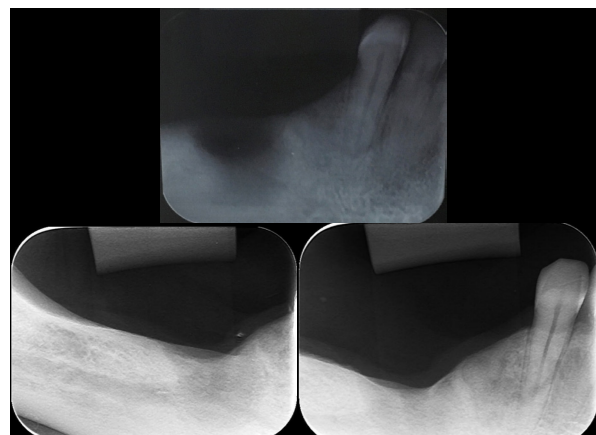


Figura 4 - A – Radiographic image 30 days after surgery; B – Radiographic image 60 days after surgery.

DISCUSSION

MO is a multifactorial disease of not fully understood etiology. It is believed that there are factors that can influence the course of the disease, which are the virulence of the causative microorganisms, the anatomical viability for the infection to spread and the host defense mechanisms.⁸ The literature states that osteomyelitis lesions originate mainly from odontogenic infection which have a polymicrobial nature in 33 to 93% of cases, secondary infections and occasional foreign bodies such as dental implants.^{5, 9, 10} The case reported here refers to the previous existence of a dental implant was previously removed.

The increasing number of infections associated with implantation and combination with the development of multidrug-resistant pathogens.¹¹ Thus, the accumulation of microorganisms on the surface of the dental implant has been considered the main etiological factor to induce the formation of inflammatory diseases that develop around the metallic structure.¹² Corroborating this principle, Yahaloom et al. 2017 corroborating this principle, they added the thesis that untreated PI can cause the clustering of pathogenic bacteria leading to a biofilm formation and massive bone resorption, which can eventually cause MO.

It is expected that the peri-implant reaction will heal normally after explantation, without interurrences. According to the literature, surgical removal associated with the use of antibiotic therapy still has a failure rate of 20%. The reasons for this high rate are the properties attributed to the pathogen *Staphylococcus Aureus*, which has the ability to invade host cells and persists intracellularly, where antibiotic activity decreases.¹¹ The information on the percentage therapeutic failure explains the reappearance of the signs and symptoms related by the patient even after the implant was removed, a condition that later progressed to chronic MO.

There is a consensus that the development of peri-implant lesions is due to implant failure, which can be early or late. When this is early, a problem occurs during the integration period and the etiology is assumed to include excessive surgical trauma, impaired healing or bacterial infection during the implantation procedures.^{9, 13} This is consistent with the case presented in this work and suggests that there was contamination during the surgical procedure as phlogistic signs were evidenced when performing the explantation associated with the finding of an unknown material around the implant being suggestive of remaining gauze, which supports the hypothesis of contamination during implant installation.

Likewise, MO can develop in any bone tissue in the body, being more present in long bones. However, in the maxillofacial region it is mentioned more frequently and to a greater extension, in the mandible.^{2, 5, 6, 7} This is due to the physical characteristic of the bone, which is denser, thinner and hypo vascularized. In addition to the fact that the posterior region, the molar teeth are found and is commonly the most affected area.^{1, 6, 8} Although the infection is usually associated with a single site, in some situations it can spread to other regions, a common condition in immunocompromised patients.¹⁴

Although MO is an initially silent disease, it can present characteristic symptoms that vary in some aspects according to the nature of the affection.^{3, 5, 6, 13, 15} The clinical presentation of this case differs from that presented in the literature in which Schlund et al. 2017 clarified that the patients had jaw pain, facial edema and periosteal abscess.

According to the anamnesis, the patient in question reported only the presence of chronic pain and purulent secretion. However on clinical evaluation, there was a bulging of the cortical bone without other significant signs. It is noteworthy that, despite not having a definitive diagnosis, the patient had been using anti-inflammatory and antimicrobial drugs for months, and this consequently, may have contributed to a frequent attenuation of the signs and symptoms of the infection, considering that such as drugs can mask the clinical manifestations as emphasized Júnior et al., 2008.

There was no consensus regarding the prevalence by gender and age, but in view of the analyzes carried out during the studies, it is assumed frequently in men between the fourth and sixth decades of life.^{2, 5, 6, 7} However, when the condition has dental implants as its etiology, this index can change, in relation to this, Chatelain et al., 2018 concluded that in 100% of the cases there was predominance in women.

In view of what has been observed, MO is a difficult condition to diagnose and is often only discovered through imaging tests. In the present study, the lesion was evaluated by means of radiography and CT, showing a greater change in the trabecular bone pattern in the posterior region of the right side, with an image suggestive of bone sequestration. This situation is consistent with the literature which emphasizes that in the chronic phase there is partial loss of bone structure along with sclerosis, subperiosteal bone formation and bone sequestration. In the case of the region, there may be thickening associated with the loss of the boundary between the bone and the medullary part.^{6, 16, 17}

Regarding the treatment performed, we opted for surgical removal associated with the use of systemic antibiotic for a week, considering that the patient was already using it for some time, as a result, the culture and antibiogram exam was waived. Although there are no records of a M) treatment protocol, the treatment chosen was in agreement with the literature consulted. Numerous authors have argued in the same direction with the main objectives of such conduct being: to remove necrotic bone, prevent the proliferation of pathogenic microorganism and provide long-term supportive care ensures efficient recovery.^{9,18}

Recurrence is low (20%) after total surgical removal of the MO and studies reported in the literature show that patients who underwent complete excision of the lesion and concomitant use of antibiotics for a long time had their symptoms eradicated and in a few cases there was persistence of the condition or the presence of pain.^{4, 16, 17, 19} Despite having a good prognosis, it is important that there is periodic follow-up for at least 2 years, so it is noteworthy that the patient in present case is already in the period of 6 months of follow-up.

CONCLUSION

It is believed that the etiology of this MO reported was a bacterial infection resulting from contamination during the insertion of dental implant, since fragments similar to gauze remnants were found during removal. Under these conditions, complete removal of the necrotic bone is necessary with the adjuvant use of at least oral antibiotics. The delay in seeking care contributed to the evolution of the condition, leading to a chronic aggressive condition. The delay in seeking care contributed to the evolution of the condition, leading to a chronic aggressive condition. The diagnosis through imaging and histopathological exams was crucial in the case, which reinforces the importance of the Dental Surgeon having a prior knowledge of the pathological lesions and their characteristics, specially when the signs and symptoms are multiple and indeterminate. Further studies on the agree topic are suggested.

REFERENCES

1. SPAZZIN, Aloísio Oro et al. Osteomielite dos maxilares. *Rev Med HSVP*, v. 16, p. 23-7, 2004.
2. RANGNE, Anders; RUUD, Astri.

Osteomyelitis of the jaws. *International journal of oral surgery*, v. 7, n. 6, p. 523-527, 1978.

3. HUDSON, J. W. Osteomyelitis of the jaws: a 50-year perspective. *Journal of Oral and Maxillofacial Surgery*, v. 51, n. 12, p. 1294-1301, 1993.
4. SAENZ-QUIROZ, Lizardo; PALACIOS-ALVA, Elmo; CASTRO-RODRÍGUEZ, Yuri. Diagnóstico y tratamiento de osteomielitis mandibular crónica. *Revista Cubana de Estomatología*, v. 58, n. 1, 2021
5. JÚNIOR, Elerson Gaetti-Jardim et al. Osteomielite crônica dos maxilares: aspectos clínicos, terapêuticos e microbiológicos. *Salusvita*, v. 27, n. 1, p. 125-39, 2008.
6. KOORBUSCH, Gerard F.; DEATHERAGE, Joseph R.; CURÉ, Joel K. How can we diagnose and treat osteomyelitis of the jaws as early as possible? *Oral and maxillofacial surgery clinics of North America*, v. 23, n. 4, p. 557-67, vii, 2011
7. SAIGAL, Anjali et al. Recurrent osteomyelitis of the mandible in osteopetrosis: a common complication of an uncommon disease. *Case Reports*, v. 2015, p. bcr2014208974, 2015.
8. WANNFORS, Karin; HAMMARSTRÖM, Lars. Infectious foci in chronic osteomyelitis of the jaws. *International journal of oral surgery*, v. 14, n. 6, p. 493-503, 1985.
9. YAHALOM, Ran et al. The Possible Role of Dental Implants in the Etiology and Prognosis of Osteomyelitis: A Retrospective Study. *International Journal of Oral & Maxillofacial Implants*, v. 31, n. 5, 2016.
10. CHATELAIN, Sybille et al. Streptococcus anginosus dental implant-related osteomyelitis of the jaws: an insidious and calamitous entity. *Journal of Oral and Maxillofacial Surgery*, v. 76, n. 6, p. 1187-1193, 2018.
11. KREIS, C. et al. Establishment of a reliable in-vivo model of implant-associated infection to investigate innovative treatment options. *Scientific Reports*, v. 12, n. 1, p. 1-14, 2022.

12. BARÃO, Valentim AR et al. Emerging titanium surface modifications: The war against polymicrobial infections on dental implants. *Brazilian Dental Journal*, v. 33, p. 1-12, 2022.
13. SCHLUND, Matthias et al. Mandibular osteomyelitis following implant placement. *Journal of Oral and Maxillofacial Surgery*, v. 75, n. 12, p. 2560. e1-2560. e7, 2017.
14. JÚNIOR, Elerson Gaetti-Jardim et al. Microbiota associated with chronic osteomyelitis of the jaws. *Brazilian Journal of Microbiology*, v. 41, n. 4, p. 1056-1064, 2010.
15. AMAND, M. Julien Saint et al. Chronic osteomyelitis of the mandible: A comparative study of 10 cases with primary chronic osteomyelitis and 12 cases with secondary chronic osteomyelitis. *Journal of stomatology, oral and maxillofacial surgery*, v. 118, n. 6, p. 342-348, 2017.
16. AGARWAL, Anuja et al. Primary chronic osteomyelitis in the mandible: a conservative approach. *Case Reports*, v. 2014, p. bcr2013202448, 2014.
17. Abdalla-Aslan R, et al. Periodic persistent orofacial pain due to osteomyelitis of the mandible: A case report. *Quintessence International*, v. 47, n. 7, 2016.
18. SUN, Hai-Jiang et al. Clinical characteristics and treatment of osteopetrosis complicated by osteomyelitis of the mandible. *Journal of Craniofacial Surgery*, v. 27, n. 8, p. e728-e730, 2016.
19. ANDRE, C.-V. et al. Osteomyelitis of the jaws: a retrospective series of 40 patients. *Journal of stomatology, oral and maxillofacial surgery*, v. 118, n. 5, p. 261-264, 2017.